



OPEN ACCESS

Management of failed rotator cuff repair: a systematic review

Alexandre Lädermann,¹ Patrick J Denard,² Stephen S Burkhart³¹Meyrin, Switzerland²Portland, Oregon, USA³San Antonio, Texas, USA**Correspondence to**Dr Alexandre Lädermann,
Meyrin 1217, Switzerland;
alexandre.laedermann@gmail.com

Received 10 November 2015

Revised 8 December 2015

Accepted 15 December 2015

Published Online First

21 January 2016

ABSTRACT**Importance** Recurrent tear after rotator cuff repair (RCR) is common. Conservative, and open and arthroscopic revisions, have been advocated to treat these failures.**Aim or objective** The purpose of this systematic review was to evaluate the different options for managing recurrent rotator cuff tears.**Evidence review** A search was conducted of level I through 4 studies from January 2000 to October 2015, to identify studies reporting on failed RCR. 10 articles were identified. The overall quality of evidence was very low.**Findings** Mid-term to long-term follow-up of patients treated conservatively revealed acceptable results; a persistent defect is a well-tolerated condition that only occasionally requires subsequent surgery. Conservative treatment might be indicated in most patients, particularly in case of posterosuperior involvement and poor preoperative range of motion. Revision surgery might be indicated in a young patient with a repairable lesion, a 3 tendon tear, and in those with involvement of the subscapularis.**Conclusions and relevance** The current review indicates that arthroscopic revision RCR can lead to improvement in functional outcome despite a high retear rate. Further studies are needed to develop specific rehabilitation in the case of primary rotator cuff failure, to better understand the place of each treatment option, and, in case of repair, to optimise tendon healing.**INTRODUCTION**

Failure of tendon healing after rotator cuff repair (RCR) is common, reported in approximately 20% of cases, depending on tear size.¹ Tear recurrence can be related to various factors such as: (1) inadequate strength of the initial repair construct, (2) biological failure to heal despite strong initial fixation and (3) inappropriate postoperative rehabilitation causing structural failure of the repair.^{2–9} While functional outcome has been correlated with postoperative rotator cuff integrity,³ many patients maintain a satisfactory outcome despite structural failure.¹⁰ The ideal treatment for a recurrent tear is thus not completely defined.

Our aim was to perform a systematic review of the literature regarding recurrent rotator cuff. The purpose was to (1) analyse postoperative techniques of evaluation of repaired rotator cuffs, (2) review the natural history of failed RCR, (3) evaluate the different treatment options, (4) determine if revision leads to better clinical and functional outcome compared with non-operative treatment and (5) identify prognostic factors associated with outcome

What is already known

- ▶ Recurrent tear after rotator cuff repair (RCR) is common. Structural failure does not always result in clinical failure. The efficacy of various treatment options has still to be determined. Arthroscopic revision RCR can lead to improvement in functional outcome; however, the retear rate may be high.
- ▶ Level of evidence: systematic review of level I-IV prognostic studies, level IV.

following revision. The hypothesis of the study was that arthroscopic revision RCR can lead to substantial improvement in functional outcome.

METHODS**Literature search**

A systematic review was performed on PubMed articles from January 2000 to October 2015. To avoid overlooking appropriate studies, no filters were applied to the search strategies. Two authors (AL and PJD) independently identified published studies addressing treatment of failed RCR. Search terms included “open and arthroscopic rotator cuff repair”, “failure”, “revision surgery”, “physiotherapy”, “non-operative”, “conservative treatment” and “postoperative imaging”. In addition, we reviewed the references of the initially identified articles. Inclusion criteria included (1) functional outcome data on treatment of failed RCR, (2) level I-IV evidence relevant to the search terms, (3) English, French or German language and (4) a minimum of 12-month follow-up. Studies that did not specifically focus on treatment of failed RCR, but that provided useful information about diagnosis and treatment outcome, were also included. Expert opinions were excluded.

Information collected included year of publication, number of shoulders included, age of participants, surgical approach (open or arthroscopic), duration of follow-up, postoperative imaging, functional outcome measures and associated prognostic factors.

Statistical analysis

Continuous data were described by mean or median value, SD, percentage and range.

RESULTS**Literature search**

The MEDLINE search identified 33 studies that focused on revision RCR.^{11–43} Fifteen studies were

Open Access
Scan to access more
free content

CrossMark

To cite: Lädermann A,
Denard PJ, Burkhart SS.
JISAKOS 2016;1:32–37.

excluded because they were reviews,^{11 14 16 17 20 23 25 27 32 36 41 43} case reports¹⁹ and commentary on studies.^{13 42} One study dealt with results of surgery after failed attempt at repair of irreparable rotator cuff tear³⁵ and six had insufficient data (ie, no distinction in the results between primary and revision cases).^{12 21 29 31 37 39} Two studies described the results²⁴ and the operative technique²⁶ of the same population. Finally, 10 met our inclusion criteria and were included in this study (table 1). All studies that met the study inclusion criteria were level IV evidence except for one (table 1).³⁸

We also identified 9 studies that described the natural history and outcome after structural failure of RCR^{3 10 44–50} and 29 studies that presented initial imaging findings. Two studies presented the outcome of the same patients at different points of follow-up.^{10 48} Postoperative scores were reported in every study, but tendon healing was only reported in four studies.^{12 24 29 38} Patient demographic characteristics and results for all included studies are shown in table 2.

Initial radiological findings

The goal of imaging studies is to confirm the site of the recurrent tear. Trantalís *et al*⁵¹ were the first to report five patients with re-tearing of the cuff after double-row RCR. All five patients had re-tearing medial to the medial row as sutures were placed near the musculotendinous junction of the supraspinatus.⁵¹ Hayashida *et al*⁵² observed that the prevalence of complete re-tearing of the tendon after a double-row RCR is similar around the medial anchors, with a well-preserved footprint. Another point of interest is the quality of the tendon.⁵³ A significant and growing number of RCRs are performed in individuals with poor rotator cuff tissue quality. Djurasovic *et al*¹⁸ reported an incidence of 30% (24 on 80) of poor rotator cuff tissue quality (graded subjectively at the time of surgery). At the same time, the muscle undergoes intrinsic degeneration. After a re-tear, Deniz *et al*⁵⁴ found that fatty infiltration and atrophy continued to worsen significantly. However, fatty infiltration of the supraspinatus does not seem to be a determinant factor in tendon healing. Park *et al*⁵⁵ did not find significant relationship between preoperative supraspinatus fatty infiltration and postoperative tendon healing. Contrarily, it seems that fatty infiltration of the infraspinatus and subscapularis is a highly significant factor ($p < 0.001$).⁵⁵ Another point is the bone quality. Oh and colleagues demonstrated that bone mineral density within the greater tuberosity decreases in patients with rotator cuff tears. In another retrospective study that investigated the relationship between greater tuberosity osteopaenia and chronicity of rotator cuff tears, Cadet *et al*⁵⁶ found that there were significantly greater osteopaenic changes in the greater tuberosity in patients with chronic retracted rotator cuff tears. However, this localised osteoporosis may not influence tendon healing. In a recent study, Park *et al*⁵⁵ did not, after primary repair, observe that bone mineral density influenced final results. Nevertheless, the greater tuberosity in revision cases can also be deficient due to anchor removal or perianchor cyst formation. Kim *et al*, in a retrospective case series of 209 patients, observed bone cyst formation in 97 instances (46.4%), and these authors questioned the utility of bioabsorbable anchors because of possible interference with revision surgery. Consequent bone lysis can be noticed after trauma. Lädermann *et al*⁵⁷ reported massive bone resorption after osteosynthesis of the greater tuberosity, leading to combined tendon and bony insufficiency, and pseudoparalysis.

Postoperative MRI are difficult to interpret.⁵⁸ Recent prospective studies have confirmed that ultrasound has a high

sensitivity and specificity for detecting a recurrent rotator cuff tear compared with MRI.^{59–62} In a study comparing MRI and ultrasound after RCR, Codsí *et al*⁵⁹ found 92% agreement with a coefficient of 0.70. Similarly, Collin *et al*⁶⁰ reported that ultrasound had 80% sensitivity and 98% specificity compared with MRI.

Conservative treatment of failed RCR

Jost *et al*¹⁰ evaluated 20 patients with a failed RCR at a mean follow-up of 38 months and reported that the adjusted Constant score and Subjective Shoulder Value (SSV) averaged 83% and 75%, respectively. Namdari *et al* demonstrated a successful outcome in 54% of patients (defined by an American Shoulder and Elbow Surgeons (ASES) score of >80 points) and a mean 15 point improvement in the ASES score at a mean of 52 months postoperatively. Finally, the same group compared the 2-year and 10-year results for patients with known structural failures of RCR. The average long-term ASES score was 79 points (range 50–95 points) and the average visual analogue scale (VAS) pain score was 2.2 points (range 1–4 points); both scores were unchanged from those at 2 years. The average Simple Shoulder Test (SST) score was 9.2 points (range 6–12 points), and the average age-adjusted Constant score was 73 points (range 59–90 points).⁵⁰

Clinical and radiological results after revision RCR

The clinical results of the 10 studies are summarised in table 2. Seven studies used an arthroscopic technique and three studies used an open technique for revision. Overall, range of motion improved, except in one series of open RCR.²² Functional outcome improved in all series and 70% or more of patients were satisfied or very satisfied.

The short-term to intermediate-term incidence of complications—including subsequent revision surgery—after revision RCR, is relatively low, around 10% in this review (table 2). However, the studies in this review primarily considered reoperation a complication and did not examine complications such as haematoma, hardware failure and postoperative stiffness. The prevalence of postoperative complications is therefore probably higher than reported. The prevalence of non-healing or re-tear was around 40% (range 0–62%) in the four studies with postoperative imaging.^{12 24 29 38} Furthermore, these tears may progress with time; Shamsudin *et al* reported a prevalence of defect of 28% at 6 months and of 40% at 2 years.

Risk factors for poorer postoperative results

Several patient-related factors appear to be associated with poorer results. Female sex^{15 28 34} and, in one study, if the surgery was performed on the dominant arm, were negatively associated with postoperative outcome.¹⁵ There is still controversy about certain risk factors such as age of patients.^{15 24 28}

Disease-related factors included patients with a recurrent tear after the revision repair,²⁴ preoperative VAS pain score greater than five²⁸ and poor preoperative range of motion.^{15 18 22 28 34 63} The ranges vary from less than 90° in the studies from Piasecki *et al*³⁴ and Denard *et al*⁶³ to 140° in the study of Chuang *et al*.¹⁵ The latter factor has been reported in almost all series and is probably the most important preoperative indicator. In addition, acromiohumeral distance (<7 mm) can be associated with a satisfactory outcome.²² There is controversy about patients with more than one prior surgery, with one study reporting that this negatively impacted results and another study reporting that it did not.^{28 34}

Systematic review

Table 1 Summary of key articles used in systematic review

Study	Year of publication	Technique	Shoulders	Age in years, mean (range)	Massive tears (% of total)	Follow-up in month, mean (range)	Design	Level of evidence
Djurasovic <i>et al</i> ¹⁸	2001	Open	80	59.0	30%	49 (25–110)	Retrospective case series	IV
Lo and Burkhart ³⁰	2004	Arthroscopic	14	57.6	79%	23.4 (12 to NA)	Retrospective case series	IV
Keener <i>et al</i> ²⁴	2010	Arthroscopic	21	55.6	NA	36 (24–50)	Retrospective case series	IV
Piasecki <i>et al</i> ³⁴	2010	Arthroscopic	54	54.9	7%	31.1 (12–78)	Retrospective case series	IV
Lädemann <i>et al</i> ²⁸	2011	Arthroscopic	74	60.8	72%	59 (24–120)	Retrospective case series	IV
Hartzler <i>et al</i> ²²	2013	Open	37	58 (41–80)	16%	7.0 (1–14.9)	Retrospective case series	IV
Parnes <i>et al</i> ³³	2013	Arthroscopic	94	52 (44–72)	54%	NA (NA to 12)	Retrospective case series	IV
Chuang <i>et al</i> ¹⁵	2014	Arthroscopic	32	69.3	59%	70.3 (13–165)	Retrospective case series	IV
Shamsudin <i>et al</i> ³⁸	2015	Arthroscopic	50	63 (43–80)	NA	35 (19–45)	Cohort study	III
Skoff ⁴⁰	2015	Open	10	58 (47–65)	0%	24 (12–44)	Retrospective case series	IV

NA, not available.

Operative-related factors, such as poor tendon quality,^{18–30} are associated with poorer results. One study compared outcomes between massive and non-massive tears and did not find any significant difference in terms of postoperative anterior elevation, pain, or functional outcome.²⁸

Postrevision rehabilitation

In all studies, participants took part in standardised rehabilitation protocols. Most studies did not allow immediate overhead passive motion.^{28–30–34} In all studies except one,⁴⁰ the sling was discontinued after 6 weeks. Strengthening was delayed until 6,³⁸ 12,^{15–18–22–30–33–34–40} to 16 weeks^{24–28} postoperatively. Full return to activity was not allowed until 4,²⁴ 6,³⁸ or even 12 months.^{15–28–30}

DISCUSSION

This systematic review summarises the current literature regarding failed RCR and confirms the hypothesis of the study that arthroscopic revision surgery can lead to substantial improvement in functional outcome. However, due to the relative small number of studies, it was not possible to reach any definitive conclusion regarding appropriate management of failed RCR. Moreover, the low methodological quality of the included studies and, subsequently, the low quality of evidence, seriously affected the strength of recommendation of the present review. Any proposed assessment and treatment algorithm therefore also includes personal experience and extrapolated scientific data that are offered for consideration.

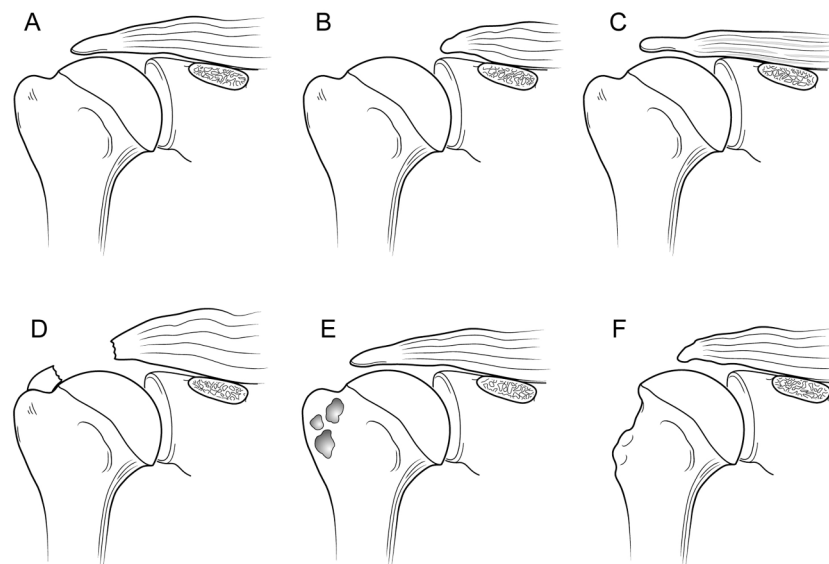
One aim of the study was to evaluate postoperative imaging. When milestones of typical postoperative recovery are not met,

Table 2 Clinical results of revision RCR

	Djurasovic <i>et al</i>	Lo and Burkhart	Keener <i>et al</i>	Piasecki <i>et al</i>	Lädemann <i>et al</i>	Hartzler <i>et al</i>	Parnes <i>et al</i>	Chuang <i>et al</i>	Shamsudin <i>et al</i>	Skoff
Active postoperative forward elevation, mean \pm SD (gain)	130° \pm NA (25)	153° \pm 33° (32)	146° \pm 29° (NA)	136° \pm 11.8° (15)	152° \pm 42° (16)	Median 110° (–20)	NA	156° \pm 17° (9)	NA (2)	NA
Postoperative ASES, mean \pm SD (gain)	NA	NA	74 \pm 24 (NA)	68 \pm 7 (24)	77 \pm 25 (26)	NA	NA	87 \pm 13 (NA)	NA	75 (57)
Postoperative UCLA, mean \pm SD (gain)	NA	28 \pm 7 (15)	NA	NA	27 \pm 7 (9)	NA	NA	30 \pm 5 (14)	NA	28 (24)
SST, mean \pm SD (gain)	NA	NA	8.9 \pm 3.2 (3.5)	7.5 \pm 1.1 (4)	NA	NA	NA	NA	NA	NA
Postoperative VAS pain score, mean \pm SD (gain)	3 (4.4)	NA	2.7 \pm 2.6 (NA)	2.7 \pm 0.8 (2.4)	2.0 \pm 2.3 (3.0)	median 5.0 (3)	NA	0.9 (3.7)	NA	NA
Patient satisfaction (%)	70	93	NA	NA	78	NA	NA	NA	NA	NA
SANE score, mean \pm SD	NA	NA	NA	68.1 \pm 8.3	74.7 \pm 20.9	NA	NA	NA	NA	NA
Non-healing or retear (%)	NA	NA	52	NA	NA	NA	10.6	NA	40	0
Complications/revision (%)	NA	0	0	11.1	8.1	2.7	9.6	NA	12	0

ASES, American Shoulder and Elbow Surgeons; NA, not available; RCR, rotator cuff repair; SANE, Single Assessment Numeric Evaluation; SST, Simple Shoulder Test; UCLA, University of California Los Angeles; VAS, visual analogue scale.

Figure 1 Six patterns of anatomic deficiency associated with failed rotator cuff repair. (A) Failure of tendon healing; (B) poor tendon quality; (C) fatty infiltration/atrophy; (D) retear medial to the medial row of fixation; (E) bone defects in the greater tuberosity after anchor removal, or perianchor cyst formation and (F) bony and tendinous insufficiency.



analysis of RCR should be considered, and a multimodal evaluation is required. The goal of imaging studies is to confirm the site of the recurrent tear (figure 1),^{52–64} the type of failure (eg, in continuity)⁶⁵ and, if possible, its cause. Other points of interest are the quality of the bone (tuberosity deficiency),⁵⁷ tendon and muscle,⁵⁴ and whether further surgery is feasible. Standard shoulder radiographs, including anteroposterior, axillary lateral and scapular Y (outlet) views, may demonstrate decreased acromiohumeral distance, glenohumeral arthritis, subacromial spurs, acetabularisation of the acromion, femoralisation of the humeral head and implant or anchor migration.^{22–66} It can also be used to rule out chondrolysis, anchor migration or prominence, and acromial fracture. Among evaluation techniques, the most widely accepted reference standard is MRI, which allows visualisation of the tendons and does not involve radiation exposure. Intra-articular contrast may be used in association with MRI to increase the sensitivity for detecting a recurrent tear.⁶¹ Postoperative MRI are difficult to interpret^{58–67}; inadequate coverage of the greater or lesser tuberosity may indicate partial healing and not a recurrent full-thickness tear.^{68–69} Furthermore, only 10% of reattached tendons generate a normal MRI signal. Thus, a common finding is the presence of an intermediate signal within the tendon, indicating granulation tissue, or of a low-intensity signal produced by fibrous tissue.^{58–69–73} These signal changes may persist for longer than 6 months, due to tissue remodelling, and seem to have no clinical implications.^{74–75} Finally, the evaluation of MRI scans is made difficult by the normal leakage of fluid into the subacromial space after the opening of the rotator interval and passage of instruments through the tendon, which may contain artefacts generated, for instance, by metal anchors or high-strength sutures. These factors, together with the high cost of MRI, lend considerable appeal to ultrasound as a method for evaluating RCR, even if its effectiveness is operator dependent.^{76–77} CT arthrogram can also be used to aid in the identification of recurrent rotator cuff tears when neither ultrasound nor MRI are options.⁷⁸ Failure after RCR was previously believed to occur during the first 3 months.^{79–80} While the majority of retears do occur within the first 3 months, it has now been demonstrated that retears can occur up to 6 months after repair.^{81–82}

Another goal of the present article was to analyse the natural history of failed RCR. Structural failure does not always result in clinical failure. Many patients with partial healing of the cuff

and a residual defect will be much improved after surgery. Characteristics associated with successful and unsuccessful results after structural failure of RCR are poorly understood. Retear or non-healing of tendons is rather frequent and surgery is rarely proposed because this condition is often well tolerated with marked clinical improvement in comparison with the pre-operative state.^{3–10–44–50} One reason for clinical failure is probably the non-restoration of balanced force couples and the suspension bridge system of force transmission in the shoulder.⁸³ The location (involvement of the subscapularis on which the rotator cable is attached) along with the size (more than 2 tendons) is the primary determinant of rotator cuff function.⁸⁴

It has long been recognised that revision RCR is challenging, as there are frequently multiple components to the pathoanatomy and multiple reasons for the failure of the initial repair. We consequently aimed to evaluate the different surgical treatment options and the prognostic factors associated with the outcomes of the procedure. The most important factor related to poor results seems to be poor preoperative range of motion. If revision is planned, patients have to be aware of the high prevalence of persistent structural defect. Moreover, retear rate after reoperation continues to deteriorate with time.^{38–85} The alarming retear rate revealed by this review indicates that several surgical options can be considered that must be individualised to the patient. For example, in the setting of an acute traumatic retear in a physiologically young, healthy, active and non-pseudoparalytic patient, arthroscopic revision surgery is generally recommended. Techniques to enhance mechanical fixation, such as linked load-sharing rip-stop constructs, should be considered.⁸⁶ Augmented repairs using scaffold devices derived from autografts,^{40–57–87} allograft,¹² xenograft extracellular matrix³⁷ or synthetic matrices such as poly-L-lactide grafts,²⁹ have been used to offer a structural support to the repair during the crucial healing period and to improve healing rates. The scientific literature does not contain enough data to justify any systematic-associated augmentation techniques. Tendon transfers may be used in patients without advanced glenohumeral arthritis who have significant loss of external rotation strength and maintain anterior active elevation.^{88–89} If the patient is young, pseudoparalytic, and suffers from a combined bony and tendinous rotator cuff insufficiency, a calcaneum and Achilles tendon allograft could be considered.⁹⁰ Finally, whereas primary pseudoparalysis responds well to arthroscopic RCR, persistent

Systematic review

pseudoparalysis after a previous attempt at RCR may be more predictably managed with reverse shoulder arthroplasty (RSA). We reported in a previous study that pseudoparalysis was reversed in the revision setting in only 43% of patients, with a low rate (54%) of satisfaction.⁶³ In contrast, Boileau *et al*⁹¹ found that anterior elevation was reliably restored with RSA after failed RCR and 73% of patients were satisfied.

Limitations

This study has several limitations. First, we were inherently limited to a review of primarily level III and IV studies, and the low quality of evidence seriously affected the strength of recommendation. We also excluded studies from journals that had insufficient data available; this lowered our sample sizes and could have introduced a selection bias. Second, no attempt was made to contact the authors of each study, to obtain individual patient data for the purposes of a meta-analysis. Third and lastly, many outcomes such as Constant score⁹² were not considered due to the paucity of studies. This lack of data or heterogeneity of the studies did not allow statistical analysis.

CONCLUSION

The current review indicates that arthroscopic revision RCR can lead to improvement in functional outcome despite a high retear rate. A clear deficiency exists in the literature concerning this topic; more research should be performed in the future to develop specific rehabilitation in cases of failure, to better understand the place of each treatment option with comparative studies and, in cases of repair, to optimise tendon healing.

Contributors AL contributed to the writing and review of the literature. PJD contributed to the review of the literature and manuscript. SSB was responsible for the planning, editing and schema.

Funding Received research support from Arthrex Inc.

Competing interests SSB is a consultant for and receives royalties from Arthrex Inc. PJD is a consultant for and receives research support from Arthrex Inc.

Provenance and peer review Commissioned; externally peer reviewed.

Open Access This is an Open Access article distributed in accordance with the Creative Commons Attribution Non Commercial (CC BY-NC 4.0) license, which permits others to distribute, remix, adapt, build upon this work non-commercially, and license their derivative works on different terms, provided the original work is properly cited and the use is non-commercial. See: <http://creativecommons.org/licenses/by-nc/4.0/>

REFERENCES

- Collin P, Abdullah A, Kherad O, *et al*. Prospective evaluation of clinical and radiologic factors predicting return to activity within 6 months after arthroscopic rotator cuff repair. *J Shoulder Elbow Surg* 2015;24:439–45.
- Bigliani LU, Cordasco FA, McIlveen SJ, *et al*. Operative treatment of failed repairs of the rotator cuff. *J Bone Joint Surg Am* 1992;74:1505–15.
- Boileau P, Brassart N, Watkinson DJ, *et al*. Arthroscopic repair of full-thickness tears of the supraspinatus: does the tendon really heal? *J Bone Joint Surg Am* 2005;87:1229–40.
- Cho NS, Moon SC, Jeon JW, *et al*. The influence of diabetes mellitus on clinical and structural outcomes after arthroscopic rotator cuff repair. *Am J Sports Med* 2015;43:991–7.
- Chung SW, Oh JH, Gong HS, *et al*. Factors affecting rotator cuff healing after arthroscopic repair: osteoporosis as one of the independent risk factors. *Am J Sports Med* 2011;39:2099–107.
- Clement ND, Hallett A, MacDonald D, *et al*. Does diabetes affect outcome after arthroscopic repair of the rotator cuff? *J Bone Joint Surg Br* 2010;92:1112–17.
- Goutallier D, Postel JM, Bernageau J, *et al*. Fatty muscle degeneration in cuff ruptures. Pre- and postoperative evaluation by CT scan. *Clin Orthop Relat Res* 1994 (304):78–83.
- Neer CS II SC. Reoperation for failed cuff repairs. Presented at the Closed Meeting of the American Shoulder and Elbow Surgeons; Orlando, FL, October, 1987.
- Neviaser RJ, Neviaser TJ. Reoperation for failed rotator cuff repair: analysis of fifty cases. *J Shoulder Elbow Surg* 1992;1:283–6.
- Jost B, Zumstein M, Pfirrmann CW, *et al*. Long-term outcome after structural failure of rotator cuff repairs. *J Bone Joint Surg Am* 2006;88:472–9.
- Abrams JS. Management of the failed rotator cuff surgery: causation and management. *Sports Med Arthrosc* 2010;18:188–97.
- Agrawal V. Healing rates for challenging rotator cuff tears utilizing an acellular human dermal reinforcement graft. *Int J Shoulder Surg* 2012;6:36–44.
- Bell JE. Repair of symptomatic rotator cuff tears after failed nonoperative treatment is cost-effective: commentary on an article by Richard C. Mather III, MD, *et al*. "The societal and economic value of rotator cuff repair." *J Bone Joint Surg Am* 2013;95:e178.
- Burkhead WZ Jr, Moen TC, Rudolph GH. General surgical principles of open rotator cuff repair in the management of failed arthroscopic cuff repairs. *Instr Course Lect* 2013;62:105–14.
- Chuang MJ, Jancosko J, Nottage WM. Clinical outcomes of single-row arthroscopic revision rotator cuff repair. *Orthopedics* 2014;37:e692–8.
- Cordasco FA, Bigliani LU. The treatment of failed rotator cuff repairs. *Instr Course Lect* 1998;47:77–86.
- Denard PJ, Burkhart SS. Arthroscopic revision rotator cuff repair. *J Am Acad Orthop Surg* 2011;19:657–66.
- Djurasovic M, Marra G, Arroyo JS, *et al*. Revision rotator cuff repair: factors influencing results. *J Bone Joint Surg Am* 2001;83-A:1849–55.
- Gee S, Dunn J, Waterman B, *et al*. Orthobiological augmentation of consecutive rotator cuff repair failure and deltoid dehiscence. *Mil Med* 2015;180:e142–4.
- George MS, Khazzam M. Current concepts review: revision rotator cuff repair. *J Shoulder Elbow Surg* 2012;21:431–40.
- Godinho GG, Franca Fde O, Freitas JM, *et al*. Result from arthroscopic surgical treatment of renewed tearing of the rotator cuff of the shoulder. *Rev Bras Ortop* 2015;50:89–93.
- Hartzler RU, Sperling JW, Schleck CD, *et al*. Clinical and radiographic factors influencing the results of revision rotator cuff repair. *Int J Shoulder Surg* 2013;7:41–5.
- Karas EH, Iannotti JP. Failed repair of the rotator cuff: evaluation and treatment of complications. *Instr Course Lect* 1998;47:87–95.
- Keener JD, Wei AS, Kim HM, *et al*. Revision arthroscopic rotator cuff repair: repair integrity and clinical outcome. *J Bone Joint Surg Am* 2010;92:590–8.
- Keener JD. Revision rotator cuff repair. *Clin Sports Med* 2012;31:713–25.
- Kowalsky MS, Keener JD. Revision arthroscopic rotator cuff repair: repair integrity and clinical outcome: surgical technique. *J Bone Joint Surg Am* 2011;93(Suppl 1):62–74.
- Lädermann A, Denard PJ, Burkhart SS. Revision arthroscopic rotator cuff repair: systematic review and authors' preferred surgical technique. *Arthroscopy* 2012;28:1160–9.
- Lädermann A, Denard PJ, Burkhart SS. Midterm outcome of arthroscopic revision repair of massive and nonmassive rotator cuff tears. *Arthroscopy* 2011;27:1620–7.
- Lenart BA, Martens KA, Kearns KA, *et al*. Treatment of massive and recurrent rotator cuff tears augmented with a poly-L-lactide graft, a preliminary study. *J Shoulder Elbow Surg* 2015;24:915–21.
- Lo IK, Burkhart SS. Arthroscopic revision of failed rotator cuff repairs: technique and results. *Arthroscopy* 2004;20:250–67.
- Ma HL, Hung SC, Wang ST, *et al*. The reoperation of failed rotator cuff repairs. *J Chin Med Assoc* 2003;66:96–102.
- Montgomery SR, Petrigliano FA, Gamradt SC. Failed rotator cuff surgery, evaluation and decision making. *Clin Sports Med* 2012;31:693–712.
- Parnes N, DeFranco M, Wells JH, *et al*. Complications after arthroscopic revision rotator cuff repair. *Arthroscopy* 2013;29:1479–86.
- Piasecki DP, Verma NN, Nho SJ, *et al*. Outcomes after arthroscopic revision rotator cuff repair. *Am J Sports Med* 2010;38:40–6.
- Postacchini F, Gumina S. Results of surgery after failed attempt at repair of irreparable rotator cuff tear. *Clin Orthop Relat Res* 2002(397):332–41.
- Scheibel M. [Recurrent defects of the rotatory cuff: causes and therapeutic strategies]. *Oper Orthop Traumatol* 2012;24:458–67.
- Sears BW, Choo A, Yu A, *et al*. Clinical outcomes in patients undergoing revision rotator cuff repair with extracellular matrix augmentation. *Orthopedics* 2015;38:e292–6.
- Shamsudin A, Lam PH, Peters K, *et al*. Revision versus primary arthroscopic rotator cuff repair: a 2-year analysis of outcomes in 360 patients. *Am J Sports Med* 2015;43:557–64.
- Sherman SL, Lyman S, Koulouvaris P, *et al*. Risk factors for readmission and revision surgery following rotator cuff repair. *Clin Orthop Relat Res* 2008;466:608–13.
- Skoff HD. Revision rotator cuff reconstruction for large tears with retraction: a novel technique using autogenous tendon and autologous marrow. *Am J Orthop (Belle Mead NJ)* 2015;44:326–31.
- Strauss EJ, McCormack RA, Onyekwelu I, *et al*. Management of failed arthroscopic rotator cuff repair. *J Am Acad Orthop Surg* 2012;20:301–9.
- Tashjian R. Turning failure into success: not always when it comes to the rotator cuff: commentary on articles by Surena Namdari, MD, MSc, *et al*, "Factors affecting outcome after structural failure of repaired rotator cuff tears," and H. Mike Kim,

- MD, *et al.*, "Factors affecting satisfaction and shoulder function in patients with a recurrent rotator cuff tear." *J Bone Joint Surg Am* 2014;96:e15.
- 43 Tonino PM, Gerber C, Itoi E, *et al.* Complex shoulder disorders: evaluation and treatment. *J Am Acad Orthop Surg* 2009;17:125–36.
- 44 Anderson K, Boothby M, Aschenbrenner D, *et al.* Outcome and structural integrity after arthroscopic rotator cuff repair using 2 rows of fixation: minimum 2-year follow-up. *Am J Sports Med* 2006;34:1899–905.
- 45 Cole BJ, McCarty LP III, Kang RW, *et al.* Arthroscopic rotator cuff repair: prospective functional outcome and repair integrity at minimum 2-year follow-up. *J Shoulder Elbow Surg* 2007;16:579–85.
- 46 Lafosse L, Jost B, Reiland Y, *et al.* Structural integrity and clinical outcomes after arthroscopic repair of isolated subscapularis tears. *J Bone Joint Surg Am* 2007;89:1184–93.
- 47 Galatz LM, Ball CM, Teefey SA, *et al.* The outcome and repair integrity of completely arthroscopically repaired large and massive rotator cuff tears. *J Bone Joint Surg Am* 2004;86:219–24.
- 48 Jost B, Pfirrmann CW, Gerber C. Clinical outcome after structural failure of rotator cuff repairs. *J Bone Joint Surg Am* 2000;82:304–14.
- 49 Namdari S, Donegan RP, Chamberlain AM, *et al.* Factors affecting outcome after structural failure of repaired rotator cuff tears. *J Bone Joint Surg Am* 2014;96:99–105.
- 50 Paxton ES, Teefey SA, Dahiya N, *et al.* Clinical and radiographic outcomes of failed repairs of large or massive rotator cuff tears: minimum ten-year follow-up. *J Bone Joint Surg Am* 2013;95:627–32.
- 51 Trantalis JN, Boorman RS, Pletsch K, *et al.* Medial rotator cuff failure after arthroscopic double-row rotator cuff repair. *Arthroscopy* 2008;24:727–31.
- 52 Hayashida K, Tanaka M, Koizumi K, *et al.* Characteristic retear patterns assessed by magnetic resonance imaging after arthroscopic double-row rotator cuff repair. *Arthroscopy* 2012;28:458–64.
- 53 Denard PJ, Burkhart SS. Techniques for managing poor quality tissue and bone during arthroscopic rotator cuff repair. *Arthroscopy* 2011;27:1409–21.
- 54 Deniz G, Kose O, Tugay A, *et al.* Fatty degeneration and atrophy of the rotator cuff muscles after arthroscopic repair: does it improve, halt or deteriorate? *Arch Orthop Trauma Surg* 2014;134:985–90.
- 55 Park JS, Park HJ, Kim SH, *et al.* Prognostic factors affecting rotator cuff healing after arthroscopic repair in small to medium-sized tears. *Am J Sports Med* 2015;43:2386–92.
- 56 Cadet ER, Hsu JW, Levine WN, *et al.* The relationship between greater tuberosity osteopenia and the chronicity of rotator cuff tears. *J Shoulder Elbow Surg* 2008;17:73–7.
- 57 Lädermann A, Denard PJ, Collin P. Massive rotator cuff tears: definition and treatment. *Int Orthop* 2015;39:2403–14.
- 58 Khazzam M, Kuhn JE, Mulligan E, *et al.* Magnetic resonance imaging identification of rotator cuff retears after repair: interobserver and intraobserver agreement. *Am J Sports Med* 2012;40:1722–7.
- 59 Codsi MJ, Rodeo SA, Scalise JJ, *et al.* Assessment of rotator cuff repair integrity using ultrasound and magnetic resonance imaging in a multicenter study. *J Shoulder Elbow Surg* 2014;23:1468–72.
- 60 Collin P, Yoshida M, Delarue A, *et al.* Evaluating postoperative rotator cuff healing: prospective comparison of MRI and ultrasound. *Orthop Traumatol Surg Res* 2015;101(6 Suppl):S265–8.
- 61 de Jesus JO, Parker L, Frangos AJ, *et al.* Accuracy of MRI, MR arthrography, and ultrasound in the diagnosis of rotator cuff tears: a meta-analysis. *AJR Am J Roentgenol* 2009;192:1701–7.
- 62 Lee KW, Yang DS, Chun TJ, *et al.* A comparison of conventional ultrasonography and arthrosonography in the assessment of cuff integrity after rotator cuff repair. *Clin Orthop Surg* 2014;6:336–42.
- 63 Denard PJ, Lädermann A, Jiwani AZ, *et al.* Functional outcome after arthroscopic repair of massive rotator cuff tears in individuals with pseudoparalysis. *Arthroscopy* 2012;28:1214–19.
- 64 Mellado JM, Calmet J, Olona M, *et al.* MR assessment of the repaired rotator cuff: prevalence, size, location, and clinical relevance of tendon rerupture. *Eur Radiol* 2006;16:2186–96.
- 65 McCarron JA, Derwin KA, Bey MJ, *et al.* Failure with continuity in rotator cuff repair "healing." *Am J Sports Med* 2013;41:134–41.
- 66 Nove-Josserand L, Edwards TB, O'Connor DP, *et al.* The acromiohumeral and coracohumeral intervals are abnormal in rotator cuff tears with muscular fatty degeneration. *Clin Orthop Relat Res* 2005(433):90–6.
- 67 Saccomanno MF, Cazzato G, Fodale M, *et al.* Magnetic resonance imaging criteria for the assessment of the rotator cuff after repair: a systematic review. *Knee Surg Sports Traumatol Arthrosc* 2015;23:423–42.
- 68 Motamed AR, Urrea LH, Hancock RE, *et al.* Accuracy of magnetic resonance imaging in determining the presence and size of recurrent rotator cuff tears. *J Shoulder Elbow Surg* 2002;11:6–10.
- 69 Spielmann AL, Forster BB, Kokan P, *et al.* Shoulder after rotator cuff repair: MR imaging findings in asymptomatic individuals—initial experience. *Radiology* 1999;213:705–8.
- 70 Mohana-Borges AV, Chung CB, Resnick D. MR imaging and MR arthrography of the postoperative shoulder: spectrum of normal and abnormal findings. *Radiographics* 2004;24:69–85.
- 71 Ruzek KA, Bancroft LW, Peterson JJ. Postoperative imaging of the shoulder. *Radiol Clin North Am* 2006;44:331–41.
- 72 Zanetti M, Hodler J. MR imaging of the shoulder after surgery. *Magn Reson Imaging Clin N Am* 2004;12:169–83.
- 73 Zanetti M, Hodler J. MR imaging of the shoulder after surgery. *Radiol Clin North Am* 2006;44:537–51.
- 74 Gerber C, Schneeberger AG, Perren SM, *et al.* Experimental rotator cuff repair. A preliminary study. *J Bone Joint Surg Am* 1999;81:1281–90.
- 75 Tudisco C, Bisicchia S, Savarese E, *et al.* Single-row vs. double-row arthroscopic rotator cuff repair: clinical and 3 Tesla MR arthrography results. *BMC Musculoskelet Disord* 2013;14:43.
- 76 Ok JH, Kim YS, Kim JM, *et al.* Learning curve of office-based ultrasonography for rotator cuff tendons tears. *Knee Surg Sports Traumatol Arthrosc* 2013;21:1593–7.
- 77 Prickett WD, Teefey SA, Galatz LM, *et al.* Accuracy of ultrasound imaging of the rotator cuff in shoulders that are painful postoperatively. *J Bone Joint Surg Am* 2003;85-A:1084–9.
- 78 Nazarian LN, Jacobson JA, Benson CB, *et al.* Imaging algorithms for evaluating suspected rotator cuff disease: Society of Radiologists in Ultrasound consensus conference statement. *Radiology* 2013;267:589–95.
- 79 Kluger R, Bock P, Mittlböck M, *et al.* Long-term survivorship of rotator cuff repairs using ultrasound and magnetic resonance imaging analysis. *Am J Sports Med* 2011;39:2071–81.
- 80 Miller BS, Downie BK, Kohen RB, *et al.* When do rotator cuff repairs fail? Serial ultrasound examination after arthroscopic repair of large and massive rotator cuff tears. *Am J Sports Med* 2011;39:2064–70.
- 81 Iannotti JP, Deutsch A, Green A, *et al.* Time to failure after rotator cuff repair: a prospective imaging study. *J Bone Joint Surg Am* 2013;95:965–71.
- 82 Kim JH, Hong IT, Ryu KJ, *et al.* Retear rate in the late postoperative period after arthroscopic rotator cuff repair. *Am J Sports Med* 2014;42:2606–13.
- 83 Denard PJ, Koo SS, Murena L, *et al.* Pseudoparalysis: the importance of rotator cable integrity. *Orthopedics* 2012;35:e1353–7.
- 84 Collin P, Matsumura N, Lädermann A, *et al.* Relationship between massive chronic rotator cuff tear pattern and loss of active shoulder range of motion. *J Shoulder Elbow Surg* 2014;23:1195–202.
- 85 Vastamaki M, Lohman M, Borgmasters N. Rotator cuff integrity correlates with clinical and functional results at a minimum 16 years after open repair. *Clin Orthop Relat Res* 2013;471:554–61.
- 86 Burkhart SS, Denard PJ, Konicek J, *et al.* Biomechanical validation of load-sharing rip-stop fixation for the repair of tissue-deficient rotator cuff tears. *Am J Sports Med* 2014;42:457–62.
- 87 Mori D, Funakoshi N, Yamashita F. Arthroscopic surgery of irreparable large or massive rotator cuff tears with low-grade fatty degeneration of the infraspinatus: patch autograft procedure versus partial repair procedure. *Arthroscopy* 2013;29:1911–21.
- 88 Gerber C, Rahm SA, Catanzaro S, *et al.* Latissimus dorsi tendon transfer for treatment of irreparable posterolateral rotator cuff tears: long-term results at a minimum follow-up of ten years. *J Bone Joint Surg Am* 2013;95:1920–6.
- 89 Pearsall AWIV, Madanagopal SG, Karas SG. Transfer of the latissimus dorsi as a salvage procedure for failed debridement and attempted repair of massive rotator cuff tears. *Orthopedics* 2007;30:943–9.
- 90 Lädermann A, Denard P, Abrassart S, *et al.* Achilles tendon allograft for an irreparable massive rotator cuff tear with bony deficiency of the greater tuberosity: a case report. *Knee Surg Sports Traumatol Arthrosc* In Press.
- 91 Boileau P, Gonzalez JF, Chuinard C, *et al.* Reverse total shoulder arthroplasty after failed rotator cuff surgery. *J Shoulder Elbow Surg* 2009;18:600–6.
- 92 Constant CR, Murley AH. A clinical method of functional assessment of the shoulder. *Clin Orthop Relat Res* 1987(214):160–4.



Management of failed rotator cuff repair: a systematic review

Alexandre Lädermann, Patrick J Denard and Stephen S Burkhart

*J ISAKOS*2016 1: 32-37 originally published online January 21, 2016
doi: 10.1136/jisakos-2015-000027

Updated information and services can be found at:
<http://jisakos.bmj.com/content/1/1/32>

These include:

Supplementary Material Supplementary material can be found at:
<http://jisakos.bmj.com/content/suppl/2016/01/21/jisakos-2015-000027.DC1>

References This article cites 86 articles, 17 of which you can access for free at:
<http://jisakos.bmj.com/content/1/1/32#ref-list-1>

Open Access This is an Open Access article distributed in accordance with the Creative Commons Attribution Non Commercial (CC BY-NC 4.0) license, which permits others to distribute, remix, adapt, build upon this work non-commercially, and license their derivative works on different terms, provided the original work is properly cited and the use is non-commercial. See: <http://creativecommons.org/licenses/by-nc/4.0/>

Email alerting service Receive free email alerts when new articles cite this article. Sign up in the box at the top right corner of the online article.

Topic Collections Articles on similar topics can be found in the following collections
[Open access](#) (4)

Notes

To request permissions go to:
<http://group.bmj.com/group/rights-licensing/permissions>

To order reprints go to:
<http://journals.bmj.com/cgi/reprintform>

To subscribe to BMJ go to:
<http://group.bmj.com/subscribe/>