



Editor's choice
Scan to access more
free content

During ACL reconstruction, small asymptomatic meniscal lesions can be left untreated: a systematic review

Nicolas Pujol, Philippe Beaufils

► Additional material is published online only. To view please visit the journal online (<http://dx.doi.org/10.1136/jisakos-2016-000051>).

Department of Orthopedic Surgery, Hospital of Versailles, Le Chesnay, France

Correspondence to

Dr Nicolas Pujol, Department of Orthopedic surgery, Hospital of Versailles, Le Chesnay 78150, France; npujol@ch-versailles.fr

Received 6 January 2016

Revised 14 March 2016

Accepted 18 March 2016

Published Online First

6 May 2016

ABSTRACT

Importance Rupture of the anterior cruciate ligament (ACL) of the knee is a commonly occurring injury in the athletic population. Associated meniscal and chondral injury is well recognised. This occurs at both the time of index injury and secondarily over time in the ACL-deficient knee. There are different treatment options to manage meniscal tears during ACL reconstruction (repair, meniscectomy, lesion left in situ) and the place of the non-operative treatment of such meniscal lesions remains unclear.

Objective This article reviews the contemporary literature about the indications and results of leaving meniscal lesions without treatment during ACL reconstructions.

Evidence review PubMed was searched for eligible studies. 15 studies met the inclusion criteria, including 1485 untreated meniscal tears (843 lateral meniscus, 642 medial meniscus).

Findings The outcomes of untreated meniscus lesions during ACL reconstruction demonstrated low rates of failures for lateral meniscus tears (between 0% and 7% if the lesion remains posterior to the popliteus tendon), whereas 12–15% of untreated medial meniscus tears underwent reoperation.

Conclusions and relevance This systematic review was in favour of leaving small lateral meniscus lesions during ACL reconstruction without additional risk of subsequent meniscectomy.

For the medial meniscus, the risk might be still present, even for small lesions.

INTRODUCTION

In the most recent studies, the mean prevalence of meniscal injuries at the time of anterior cruciate ligament (ACL) reconstruction is 35–40% for the medial meniscus and 40–45% for the lateral meniscus.^{1–4}

The healing potential of a torn meniscus depends on the location of the tear, the type and length of tear, stability, the blood supply and the degree of meniscus degeneration: stable, partial and vertical tears in the peripheral zone have a greater potential to heal.⁵

The treatment of meniscal lesions and ACL is inter-related. ACL reconstruction in an unstable knee plays a key role in the healing of the concomitant meniscal lesion and its consequences for the natural history of the joint. On the other hand, the type of treatment of these meniscal lesions can affect the outcome (stability, function, symptoms) of an ACL reconstruction.

The rationale of treatment during an ACL reconstruction is always to preserve as much of meniscal

What is already known

Meniscus lesions left untreated is a common, but undervalued, occurrence in surgical procedures for anterior cruciate ligament (ACL) reconstruction.

What are the new findings

- The rate of untreated meniscus lesions during ACL reconstruction is from 11% to 35% in the literature.
- When left untreated, the risk of subsequent surgery of these lesions is low, especially on the lateral meniscus. This 'treatment' could be used more often without additional risk of subsequent surgery.
- There is still a need for long-term and comparative studies.

tissue as possible, and a meniscectomy would be justified only if the meniscus lesion cannot be repaired or is left untreated. Although meniscal preservation is important for both stability and chondroprotection, leaving meniscal lesions untreated during ACL reconstruction may be beneficial when compared with performing meniscectomy. The purpose of this study was to investigate the outcomes of meniscal lesions left untreated during ACL reconstruction. Our hypothesis was that there would be differences in outcome according to the side of the meniscal lesion (medial or lateral).

METHOD

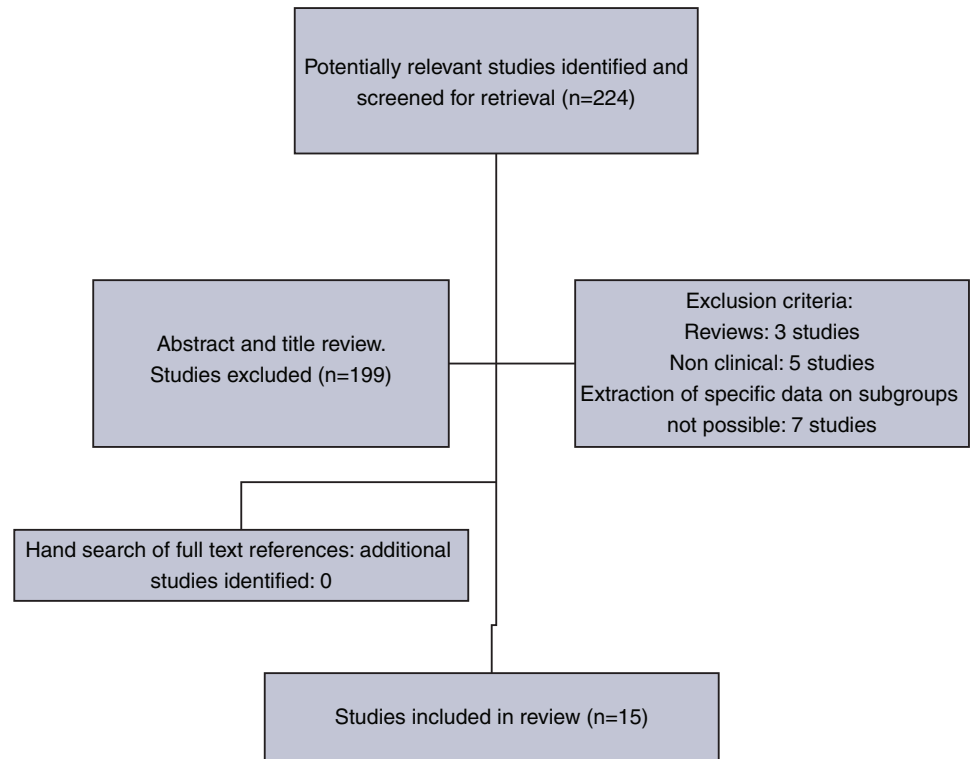
An electronic search of PubMed was performed for articles published from January 1980 to November 2015 on clinical studies looking at outcomes of meniscus tears left in situ at the time of ACL reconstruction. Search strategies were created to include the Medline keywords 'knee', 'Anterior Cruciate ligament', 'meniscus tear' or 'meniscal tear', 'left in situ' or 'let alone' or 'non-operative'. The flow chart in [figure 1](#) shows the review process from the original search to those included in the final study. The initial search yielded 224 eligible studies. Review of the abstracts of the identified studies was performed. Letters, biomechanical studies and non-English language papers were excluded. All the remaining manuscripts were reviewed (30).



CrossMark

To cite: Pujol N, Beaufils P. *JISAKOS* 2016;1:135–140.

Figure 1 Literature search outlining reasons for exclusion of identified articles.



Literature reviews, non-clinical studies and studies with no possibilities of subgroup extraction of data were also excluded. Using the above criteria, this process of exclusion yielded 15 studies. Citation tracking did not add any studies.

Data from the original articles were extracted using a standardised extraction form, including study design, number of patients, mean age at time of surgery, mean duration of follow-up, timing of surgery, surgical method used, clinical outcome, functional outcome, anatomical outcome, and complications such as reoperation rate and persisting pain.

Data were then compiled in tabular form (tables 1 and 2), depending on the side of the meniscus involved (lateral or medial).

RESULTS

General findings

The 15 original studies retrieved from our systematic search, with a total of 1485 participants (843 lateral meniscus, 642 medial meniscus), included 13 level IV and 2 level III evidence-based medicine studies. These studies were conducted among different study populations and included different outcome measures (questionnaire, patient satisfaction, residual pain, functional outcomes scales, return to sports, reoperation rate, healing rate of the meniscus). There were no studies with control groups of operatively treated meniscal lesions that could be left in situ without treatment.

The mean follow-up ranged from 16 to 72 months. The mean age at the time of surgery was 25 years (20–28).

Tears were mainly located peripherally in the vascularised area. When evaluated, the length of the tear ranged from 5 to 25 mm. The mean time from ACL injury to surgery varied between studies from 13 to 58 months.

For the lateral meniscus, there were 175 partial thickness tears and 417 complete or full-thickness tears. The remaining 242 tears could not be classified. For the medial meniscus, there

were 160 partial thickness tears, 442 complete or full-thickness tears. Forty tears could not be classified.

Lateral meniscal tears left in situ

In general, lateral tears were more frequently left untreated as compared with tears left untreated in the medial compartment¹³ (table 1).

The results of the series included in this review showed that small stable lateral meniscus tears seen with ACL reconstruction may be left in situ without high risk of reoperation. The reoperation rate for either incomplete or small lesions (<1 cm) was from 0% to 1.5%, and from 0% to 7.1% for larger lesions.^{5 7 10–14 16–19 22 23}

There was only one case–control study (level III) available in the literature.¹⁷ This study concluded that stable posterior segment tears of the lateral meniscus left untreated at the time of ACL reconstruction revealed successful clinical outcomes compared with isolated ACL injuries without meniscus tear, and showed considerable healing and functional restoration of tears with repeat MRI and second-look arthroscopy.

Another important factor is that lateral meniscus tears are often well tolerated and can be left untreated hoping they will continue to provide support. Indeed, the rate of residual meniscal symptoms (minor discomfort or pain) after such untreated lesions is low, from 0% to 5.7% on the lateral side.

If the lesion is located posteriorly to the popliteal hiatus, it could be left untreated,⁶ whatever the size of the lesion (from partial thickness tears to longitudinal tears up to 2 cm in length), with good results and no additional risk of subsequent surgery (figure 2, see online supplementary video 1).

Medial meniscal tears left in situ

The results of these series on medial meniscus were slightly different from those of the series on the lateral meniscus (table 2).

Table 1 Lateral meniscus tears left in situ during anterior cruciate ligament reconstruction

Author	n	Mean length of tear (mm)	Type of tear	Selection criteria for treatment	Mean follow-up (months)	Clinical assessment	Clinical score/100	Pain or mechanical symptoms (%) without treatment	Meniscectomy or repair (%)	Anatomical control	Healing	Procedure
Weiss ⁵	9	–	Incomplete	Incomplete	29 (6–79)	Lysholm	–	0	22	Arthroscopy	55% Healed 22.5% Unhealed 22.5% Extended	Left untreated
	15	–	Full thickness tear	Stable	27.3 (6–100)			0	1.3		45.6% Healed 40% Unhealed 13.4% Extended	
Talley ¹²	25	<15	Full thickness tear	Stable	38	Yes	–	0	4	–	–	Left untreated
Pierre ¹⁴	35	10±4 (5–20)	Full thickness tear	Stable <20 mm	48	IKDC	–	–	0	–	–	Left untreated
Yagishita ¹⁸	42	10.8 (5–25)	18 Incomplete 24 Full thickness tears	Stable <15 mm	18.3	IKDC	–	7	7.1	Arthroscopy	74% Healed 5% Partially healed 14% Unhealed 7% Tear extended	Left untreated
Zemanovic ²²	23	–	Incomplete	Incomplete	24.6	Lysholm	92.1	–	0	–	–	Left untreated
Shelbourne ¹⁷	239	–	Full thickness tear	Stable	79	Noyes	93.8	2.5	3.3	–	–	Left untreated /abrasion– trephination
Fitzgibbons ¹¹	189	–	Full thickness and incomplete tears	Stable	31.2	Noyes	92.2 (48–100)	0	0	–	–	Abrasion– trephination
Lynch ¹²	22	–	–	Stable	45.6 (36–120)	Yes	–	18	0	–	–	Left untreated
Beaufils ¹⁶	8	–	Full thickness tear	Stable	26 (12–40)	Yes	–	0	0	Arthroscopy (2) or arthrography (11)	61% Healing 38% Partial healing 1% Unhealed	Left untreated
Ichinohe ¹⁹	11	–	Small or incomplete	Posterior to popliteus tendon	16	No	–	0	0	Arthroscopy	71.7% Healed, 28.3% partially or unhealed	Left untreated
Uchio ²³	13 22	10–33	Incomplete Full thickness tear	Incomplete Stable	22	–	–	5.7%	0	Arthroscopy	71.5% Healed 22.8% Partially healed 5.7% Unhealed	Raspings
Duchman ¹³	112 25	9.5±3.9	Incomplete Full thickness tear	None	>72	–	–	?	1.5 0.7	No	–	Left untreated
Lee ⁷	53	–	50.9% Radial, 41.5% longitudinal, 7.5% small flaps	Stable	36.5	IKDC	87.6	0%	0	Arthroscopy	75% Healed 17.9% Partially healed 7.1% Unhealed	Left untreated
						Lysholm	91.3					

Table 2 Medial meniscus tears left in situ

Author	n	Mean length of tear (mm)	Type of tear	Selection criteria for treatment	Follow-up (months)	Clinical assessment	Clinical score/100	Pain or mechanical symptoms (%)	Meniscectomy or repair (%)	Anatomical control	Healing	Procedure
Beaufils ¹³	23	8	Full thickness tear	Stable	26	Yes	–	17	0	Arthroscopy (2) or arthrography (11)	61% Healing 38% Partial healing 1% Unhealed	Left untreated
Talley ¹²	19	<15	Full thickness tear	Stable	38	–	–	0	21	–	–	Left untreated
Pierre ¹⁴	60	9.8±4 (5–20)	Full thickness tear	Stable <2 mm	48	IKDC	–	–	17	–	–	Left untreated
Yagishita ¹⁸	41	12 (5–25)	16 Full thickness tears 25 Incomplete	Stable <15 mm	16 (7–41)	Yes	–	12	7.3	Arthroscopy	54% Healed 7% Partially healed 27% Unhealed 12% Tear extended	Left untreated
Zemanovic ²²	8	–	Incomplete	Partial thickness tear	24.6	Lysholm	92.1	–	0	–	–	Left untreated
Shelbourne ¹⁷	139	–	Full thickness tear	Stable <10 mm	88 233	Questionnaire –	93.1 95.4	5 4.3	10.8 6	– –	– –	Left untreated Abrasion– trephination
Lynch ¹⁰	9	–	–	Stable	45.6 (36–120)	Yes	–	66	0	–	–	Left untreated
Weiss ⁵	6	–	Incomplete tears	Partial thickness tear	21.8 (3–50)	Lysholm	–	0	33	Arthroscopy	50% Healed 50% Unhealed	Left untreated
	2	–	Full thickness tear	Stable	27.5 (25–30)			0	0		50% Healed 50% Unhealed	
Duchman ¹³	4 67	9.2±2.9	Full thickness tears Incomplete tears	–	>72	–	–	–	0 5.6	–	–	Left untreated
Ishinohe ¹¹	8		Full thickness tear or incomplete	Stable	16			0	25	Arthroscopy	50% Healed, 50% unhealed	Left untreated
Vermesan ²¹	23	5–10	8.3% Radial, 25.5% horizontal, 76.2% longitudinal	Stable	12	IKDC	95.7	–	–	–	–	Left untreated

Residual pain and/or need for a subsequent meniscectomy were reported in up to 15% of cases. The results were not different when considering partial thickness and full thickness lesions separately.^{6 12 14–16 18–21 23}

Duchman *et al*¹³ recently reported a trend towards more reoperations in medial compartment tears as compared with lateral compartment tears left untreated (12.7% vs 5.1%, respectively; $p=0.052$).

This could be explained by the influence of the posterior segment of the medial meniscus on anteroposterior (AP) stability and rotational laxity. Ahn *et al*,¹⁵ in an experimental study, reported that longitudinal lesions of the posterior segment of the medial meniscus in an ACL-deficient knee altered knee kinematics and that repair of these lesions improved AP translation (figure 2).

DISCUSSION

Treatment options of meniscal lesions during ACL reconstruction

There are very limited data in the literature comparing meniscectomies, repairs and lesions left in situ during ACL reconstruction.²⁴ This might be due to the insufficient available data to analyse the effects of tear size, and patient and surgeon characteristics.

Kluczynski *et al*,³ in 2015, reported a total of 211 lateral meniscal tears (35.3% untreated, 48.3% meniscectomised, 16.4% repaired) and 197 medial meniscal tears (25% untreated, 52% meniscectomised, 23% repaired) among 541 ACL reconstructions. They analysed predictors of associated intra-articular injuries (meniscal lesions, chondral lesions) at the time of ACL reconstruction. Male sex predicted lateral meniscal tears and management. Male sex, sport injuries 6 weeks from surgery and preoperative episodes of instability, predicted medial meniscal tears and management.

Therefore, to be a male would be the worst prognosis factor of having a meniscectomy of a torn meniscus during ACL reconstruction. What about the type of lesion?

Size of meniscal lesions

In the MOON cohort study, Duchman *et al*¹³ reported that tears measuring more than 10 mm underwent reoperation more frequently than tears measuring 10 mm or less (11.5% vs 3.2%, respectively; $p=0.035$). This relationship was not seen when

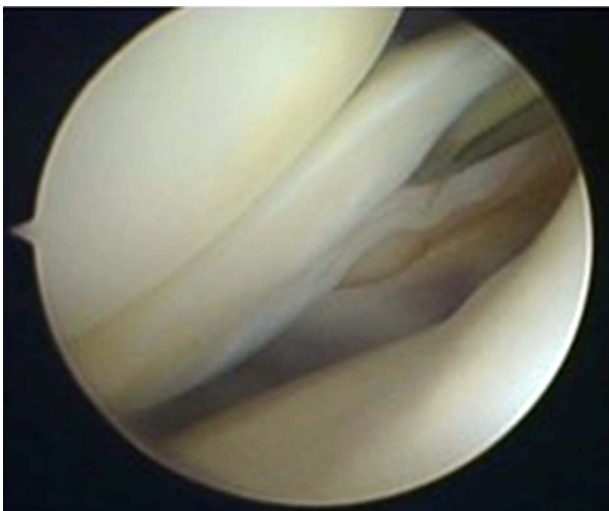


Figure 2 Lateral meniscal tear left in situ.

excluding tears treated in the setting of concomitant revision ACL reconstruction.

Rasping

The aim of rasping, proposed by Ochi *et al*⁸ 20 years ago, was to induce vascularity from the peripheral vascular area to tears in the avascular zone without drastically changing the meniscal architecture. The described procedure involved rasping the surface of the meniscus from the parameniscal synovium to the inner portion, including the longitudinal tear, using an electrical diamond burr without sutures.⁹ Experimental study showed that this procedure promoted synovial ingrowth on the rasped meniscal surface to the tear in the avascular zone, leading to good meniscal healing. Several cytokines were noted on the rasped meniscal surface; these are closely related to the healing mechanism.

Trends and factors associated with meniscal treatment during ACL reconstruction

Recently, in the Norwegian registry, 2520 lateral meniscal lesions were found in 10 468 primary ACL reconstructions. Of these, a meniscectomy was performed in 71.2% of cases, a meniscal repair in 12.8%, and the meniscus was left in situ in 15.5% of cases.⁴ Of the 3208 medial meniscal lesions found in the same cohort, 24.3% were repaired, 64% were resected and 11.6% were left in situ.

In 2013, Abrams *et al*²⁵ published a review on the trends of knee arthroscopic procedures performed from 2005 to 2011, using a national database compiled from a collection of private insurance records. There was no significant increase in the total number of meniscectomies performed ($p=0.712$), while the incidence of meniscectomies increased 14% from 2005 to 2011. There were no significant changes in the number of meniscus repairs performed at the same time as ACL reconstruction during the study frame. This indicates that there is no recent trend towards meniscal repair instead of meniscectomy during ACL reconstruction. Nevertheless, the total number and incidence of secondary meniscectomies after repair significantly decreased, indicating that the accuracy of the meniscal repair procedure improved in this period.

In 2012, Noyes and Barber-Westin²⁶ performed a systematic literature review of articles on the treatment of meniscus tears during ACL reconstruction. There were 19 531 patients with 11 711 meniscus tears who met the inclusion criteria. This study reported that 26% of meniscus tears were repaired, 65% were treated by meniscectomy and only 9% were left in situ. The difference between lateral and medial menisci was not clearly seen.

In a study on meniscal repair and ACL reconstruction by Wyatt *et al*,²⁷ meniscectomies and meniscus tears left in situ were pooled in the same control group and referred to as alternative treatment. However, four different subgroups according to the meniscus status must always be addressed separately during ACL reconstruction: no meniscal lesion, meniscal repair, meniscectomy and meniscal lesion left untreated.²⁸

Limitations

There are a high number of limitations in this literature review.

All the case series were retrospective and non-homogeneously described. Not all of the parameters analysed in the tables were reported in every article, these include: tear length, distance of the lesion to the meniscosynovial junction, high number of unclassified medial and lateral meniscus lesions, time from injury to surgery and even postoperative rehabilitation. In the referenced studies, there were no clear differences between

studies of meniscus lesions left in situ without any treatment compared with lesions left in situ without suture but with a concomitant synovial abrasion to promote healing.

CONCLUSIONS

The rationale for treatment during an ACL reconstruction is always to preserve as much meniscal tissue as possible, and a meniscectomy would be justified only if the meniscus cannot be repaired or the tear was left in situ without treatment.

Regarding this literature review, leaving small meniscal lesions alone without treatment can be recommended, especially on the lateral side, unless they are causing symptoms that warrant treatment. During ACL reconstruction, a meniscal lesion should first be considered for preservation (meniscal lesion that can be left in situ in 30–40% of cases, meniscal repair in 40–45% of cases), and only as a last resort referred for resection (unsalvageable lesions in 15–20% of cases). If a meniscectomy is needed, the amount of removed tissue should involve only the lesion (partial meniscectomy).

Future papers should consider the use of standardised classification, for example, the International Society of Arthroscopy, Knee Surgery and Orthopaedic Sports Medicine (ISAKOS) classification of meniscal tears. This may help to provide more homogeneous and comparable data in different studies.

Moreover, there is a need for long-term follow-up studies, in order to determine if these recommendations can prevent degenerative changes in the joint after an ACL reconstruction.

Competing interests None declared.

Provenance and peer review Commissioned; externally peer reviewed.

REFERENCES

- Brambilla L, Pulici L, Carimati G, et al. Prevalence of associated lesions in anterior cruciate ligament reconstruction: correlation with surgical timing and with patient age, sex, and body mass index. *Am J Sports Med* 2015;43:2966–73.
- Borchers JR, Kaeding CC, Pedroza AD, et al. Intra-articular findings in primary and revision anterior cruciate ligament reconstruction surgery: a comparison of the MOON and MARS study groups. *Am J Sports Med* 2011;39:1889–93.
- Kluczynski MA, Marzo JM, Bisson LJ, et al. Factors associated with meniscal tears and chondral lesions in patients undergoing anterior cruciate ligament reconstruction: a prospective study. *Am J Sports Med* 2013;41:2759–65.
- Granán LP, Inacio MC, Maletis GB, et al. Intraoperative findings and procedures in culturally and geographically different patient and surgeon populations: an anterior cruciate ligament reconstruction registry comparison between Norway and the USA. *Acta Orthop* 2012;83:577–82.
- Weiss CB, Lundberg M, Hamberg P, et al. Non-operative treatment of meniscal tears. *J Bone Joint Surg Am* 1989;71:811–22.
- Shelbourne KD, Gray T. Meniscus tears that can be left in situ, with or without trephination or synovial abrasion to stimulate healing. *Sports Med Arthrosc* 2012;20:62–7.
- Lee DW, Jang HW, Lee SR, et al. Clinical, radiological, and morphological evaluations of posterior horn tears of the lateral meniscus left in situ during anterior cruciate ligament reconstruction. *Am J Sports Med* 2014;42:327–35.
- Ochi M, Uchio Y, Okuda K, et al. Expression of cytokines after meniscal rasping to promote meniscal healing. *Arthroscopy* 2001;17:724–31.
- Okuda K, Ochi M, Shu N, et al. Meniscal rasping for repair of meniscal tear in the avascular zone. *Arthroscopy* 1999;15:281–6.
- Lynch M, Henning CE, Glick KR Jr, et al. Knee joint surface changes. Long-term follow-up meniscus tear treatment in stable anterior cruciate ligament reconstructions. *Clin Orthop Relat Res* 1983;172:148–53.
- Fitzgibbons RE, Shelbourne KD. "Aggressive" nontreatment of lateral meniscal tears seen during anterior cruciate ligament reconstruction. *Am J Sports Med* 1995;23:156–9.
- Talley MC, Grana WA. Treatment of partial meniscal tears identified during anterior cruciate ligament reconstruction with limited synovial abrasion. *Arthroscopy* 2000;16:6–10.
- Duchman KR, Westermann RW, Spindler KP, et al. The fate of meniscus tears left in situ at the time of anterior cruciate ligament reconstruction: a 6-year follow-up study from the MOON cohort. *Am J Sports Med* 2015;43:2688–95.
- Pierre A, Hulet C, Locker B, et al. [Outcome of 95 stable meniscal tears left in place after reconstruction of the anterior cruciate ligament]. *Rev Chir Orthop Reparatrice Appar Mot* 2001;87:661–8.
- Ahn JH, Bae TS, Kang KS, et al. Longitudinal tear of the medial meniscus posterior horn in the anterior cruciate ligament-deficient knee significantly influences anterior stability. *Am J Sports Med* 2011;39:2187–93.
- Beaufils P, Bastos R, Wakim E, et al. [Meniscal injury in the plastic reconstruction of the anterior cruciate ligament. Meniscal suture or abstention]. *Rev Chir Orthop Reparatrice Appar Mot* 1992;78:285–91.
- Shelbourne KD, Heinrich J. The long-term evaluation of lateral meniscus tears left in situ at the time of anterior cruciate ligament reconstruction. *Arthroscopy* 2004;20:346–51.
- Yagishita K, Muneta T, Ogiuchi T, et al. Healing potential of meniscal tears without repair in knees with anterior cruciate ligament reconstruction. *Am J Sports Med* 2004;32:1953–61.
- Ichinohe S, Yoshida M, Murakami H, et al. Meniscal tearing after ACL reconstruction. *J Orthop Surg (Hong Kong)* 2000;8:53–9.
- Vermesan D, Prejbeanu R, Laitin S, et al. Meniscal tears left in situ during anatomic single bundle anterior cruciate ligament reconstruction. *Eur Rev Med Pharmacol Sci* 2014;18:252–6.
- Shelbourne KD, Rask BP. The sequelae of salvaged nondegenerative peripheral vertical medial meniscus tears with anterior cruciate ligament reconstruction. *Arthroscopy* 2001;17:270–4.
- Zemanovic JR, McAllister DR, Hame SL, et al. Nonoperative treatment of partial-thickness meniscal tears identified during anterior cruciate ligament reconstruction. *Orthopedics* 2004;27:755–8.
- Uchio Y, Ochi M, Adachi N, et al. Results of rasping of meniscal tears with and without anterior cruciate ligament injury as evaluated by second-look arthroscopy. *Arthroscopy* 2003;19:463–9.
- Beaufils P, Hulet C, Dhenain M, et al. Clinical practice guidelines for the management of meniscal lesions and isolated lesions of the anterior cruciate ligament of the knee in adults. *Orthop Traumatol Surg Res* 2009;95:437–42.
- Abrams GD, Frank RM, Gupta AK, et al. Trends in meniscus repair and meniscectomy in the United States, 2005–2011. *Am J Sports Med* 2013;41:2333–9.
- Noyes FR, Barber-Westin SD. Treatment of meniscus tears during anterior cruciate ligament reconstruction. *Arthroscopy* 2012;28:123–30.
- Wyatt RW, Inacio MC, Liddle KD, et al. Factors associated with meniscus repair in patients undergoing anterior cruciate ligament reconstruction. *Am J Sports Med* 2013;41:2766–71.
- Pujol N, Beaufils P. Healing results of meniscal tears left in situ during anterior cruciate ligament reconstruction: a review of clinical studies. *Knee Surg Sports Traumatol Arthrosc* 2009;17:396–401.